

تجسم ذهنی در اندودنتیکس: زندگی در جایی که هرگز نمی بینید!

نوشته دکتر L. Stephen Buchanan

۱۱ ژوئن ۲۰۱۳

ترجمه دکتر شهرام دانش دوست

برگرفته از سایت www.dentistrytoday.com

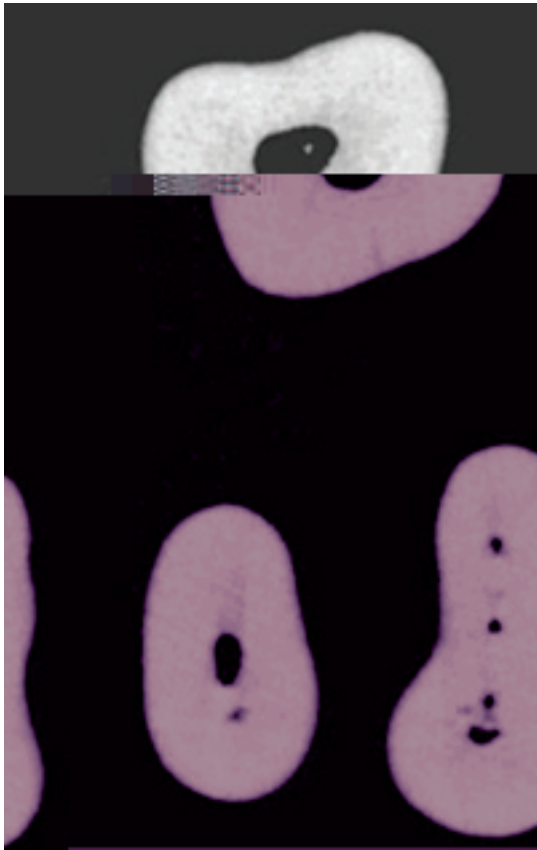
مقدمه

! «

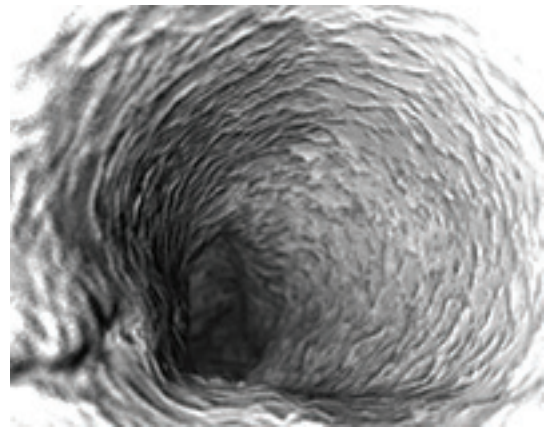
»!

Alan Gluskin

" "



CT .2



.1

(
.(Markus Haapasalo

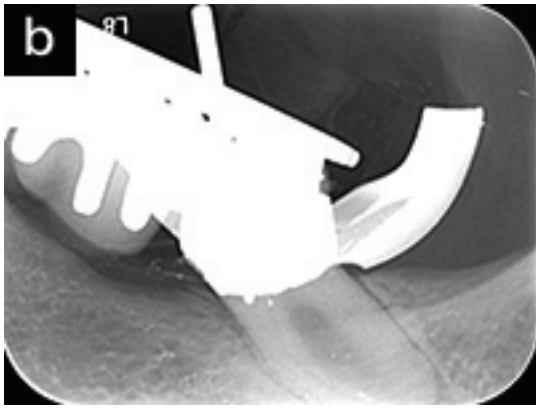
ساختن تصاویر ذهنی

" "

" " :

" "

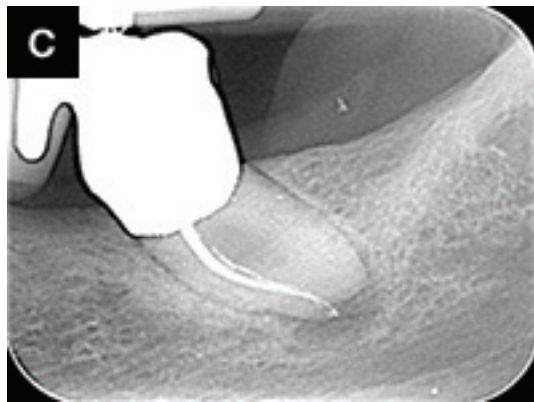
.(1 () (



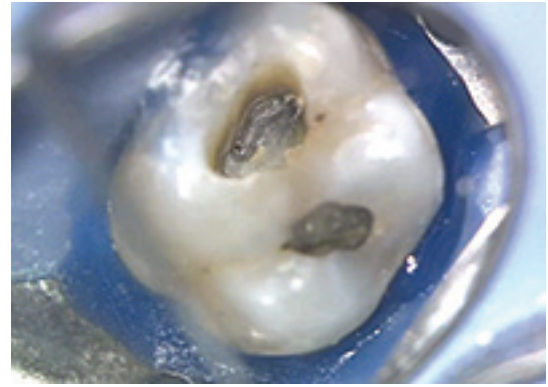

12 .3-2



9 .3-1



.3-3



.5-1
10 K ³TrueTooth

MB2 .4

)Obtura Spartan) BUC-1
1 MB1 MB2
2

MB2

MB2



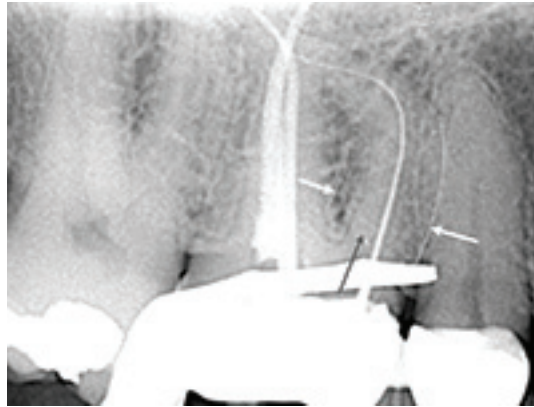
.5-2

)tug-back (

System-B

BUC

Isthmus - 1
Dust-Filled - 2
True Tooth : - 3
True Tooth . Buchanan



.6

15 К

.MB1

) () (

RCT

CT

10 5

71 (

(7-3

CBCT

11 .

CT

MB3

PA

-

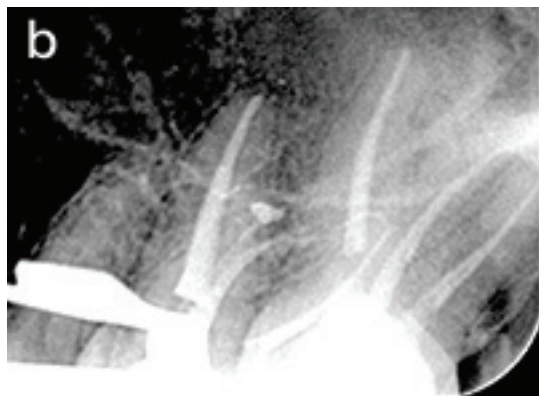-

-

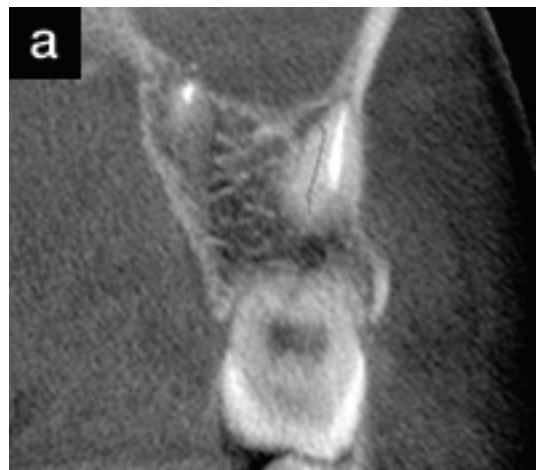CT

) 250 CT

RCT



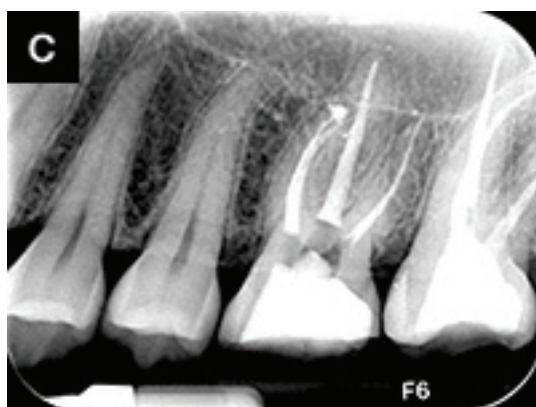.7-2
MB2



CT .7-1
MB2

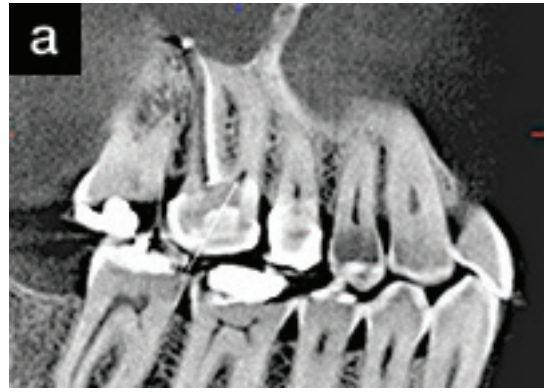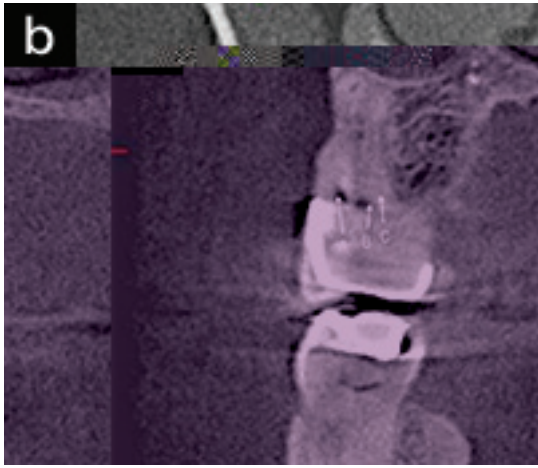
MB1

MB2



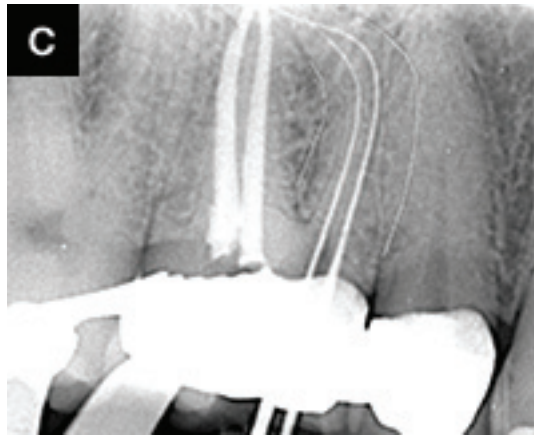
.7-3

دید مستقیم



CT .8-1
MB2

: CT .8-2
)b(MB1)a(
)c(MB2
) MB2
(




.8-3

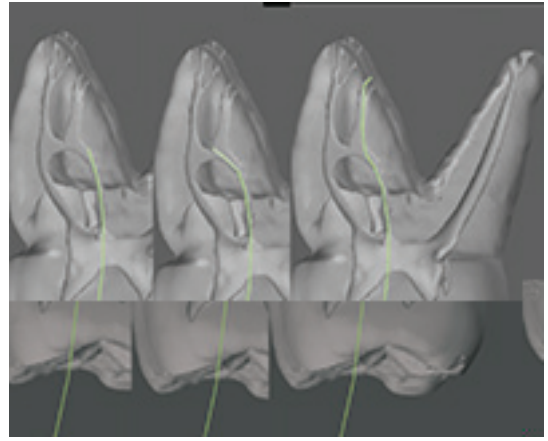
MB2 MB1
CT

MB2

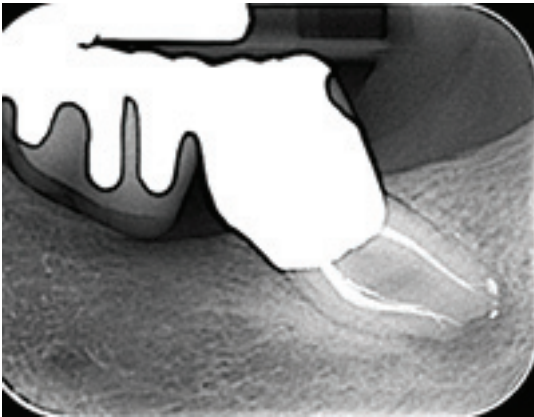
)) (((Obtura Spartan) BUC-2



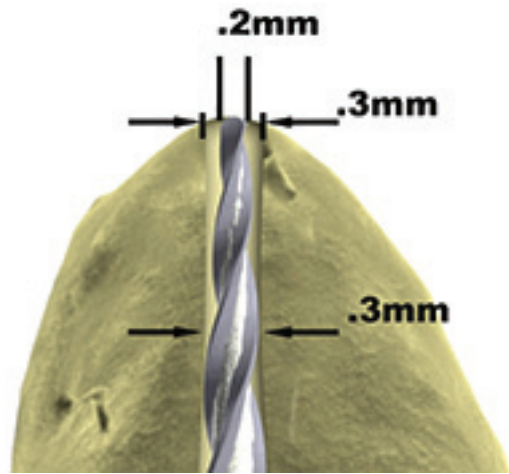
.10
MB2



CT **.9**
(MB2
)1(:
MB2
MB1
)2(
s-curve
)3(
patency



.12



.11

2

1

.)10 (

MB2

MB2

90

ارزیابی چشمی

.)11 (

تشخیص

1

System-B

خلاصه

(12.)