FRACTURES IN CHILDREN

Dr. Troncillo
June 13, 2014
Group 2 – Operation Twoli

SKELETAL DIFFERENCES BET. ADULT AND CHILDREN

- Pediatric bone is more elastic → unique fracture pattern (torus/buckle fracture; greenstick fracture)
  - Torus is an incomplete fracture. It can only be found in children.
- Thicker periosteum remains intact on one side → periosteal hinge helps in reduction
- Open physes (growth plate) can allow remodelling and straightening of a malunited fracture
- In case of growth disturbance, ongoing ingrowth can result in angular deformity or limb length discrepancy

Torus Fracture

Torus fractures (also known as **buckle fractures**) are incomplete fractures of the shaft of a long bone that is characterised by bulging of the cortex. They usually result from trabecular compression from an axial loading force (along long axis of bone). radial metaphysis.

GROWTH PLATE/PHYSEAL FRACTURE

- A fracture of the growth plate is an injury unique to childhood.
- Most such fractures heal without permanent deformity.
- A small percentage, however, are complicated by growth arrest and subsequent deformity.
- The **Salter-Harris classification** of growth plate injuries aids in estimating both the prognosis and the potential for growth arrest
  - Most commonly used classification

SALTER- HARRIS FRACTURE CLASSIFICATION

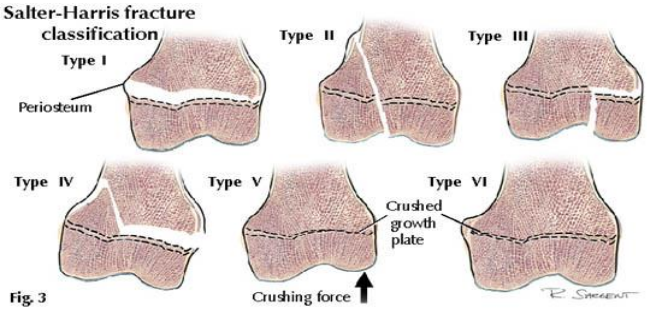

GROWTH DISTURBANCES

- Approximately 30 % of all physeal injuries will result in some measurable shortening or angulation.
- Only 2 % will significantly interfere with function.
- Lower extremity shortening and deformities cause more functional limitations because it is a weight-bearing area of our body.

Salter-Harris Fracture: Type I

- The epiphysis is <u>completely separated from the end of the bone, or the metaphysis</u>.
- The vital portions of the growth plate remain attached to the epiphysis.
- All type I injuries generally require a cast to keep the fracture in place as it heals.
- Unless there is damage to the blood supply, the likelihood that the bone will grow normally is excellent.
  - No visible deformity since the fracture is in line with growth plate

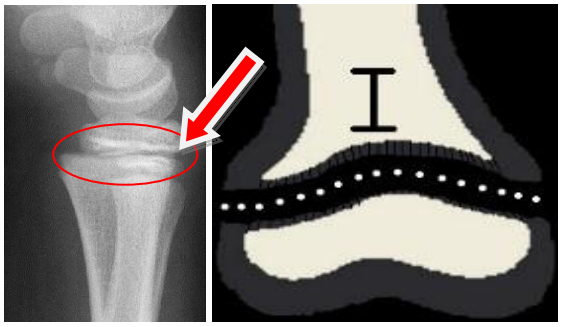

Salter-Harris Fracture: Type II

- This is the most common type of growth plate fracture.
- The <u>epiphysis, together with the growth plate, is partially separated from the metaphysis</u>, which is cracked.
- Unlike type I fractures, type II fractures typically have to be put back into place and immobilized for normal growth to continue.

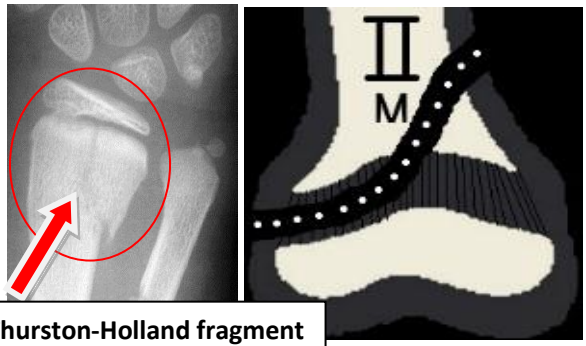

Thurston-Holland fragment - detached metaphyseal fragment

Salter-Harris Fracture: Type III

- This fracture occurs only rarely, usually at the lower end of the tibia, one of the long bones of the lower leg.
- It happens when a fracture runs completely through the epiphysis and separates part of the epiphysis and growth plate from the metaphysis.
- Surgery is sometimes necessary to restore the joint surface to normal *coz it's at the articular part of the long bone
- The outlook or prognosis for growth is good if the blood supply to the separated portion of the epiphysis is still intact, if the fracture is not displaced, and if a bridge of new bone has not formed at the site of the fracture.

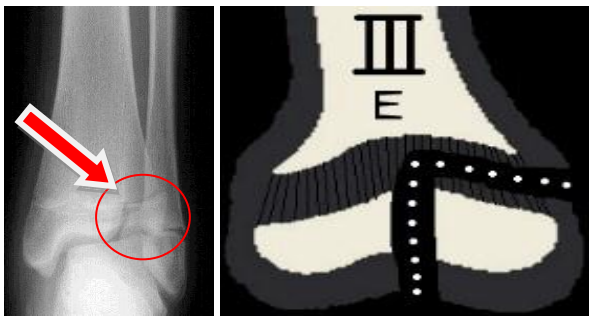

Salter-Harris Fracture: Type IV

- This fracture runs through the epiphysis, across the growth plate, and into the metaphysis.
- Surgery is needed to restore the joint surface to normal and to perfectly align the growth plate.
- Unless perfect alignment is achieved and maintained during healing, prognosis for growth is poor.
- This injury occurs most commonly at the end of the humerus (the upper arm bone) near the elbow.

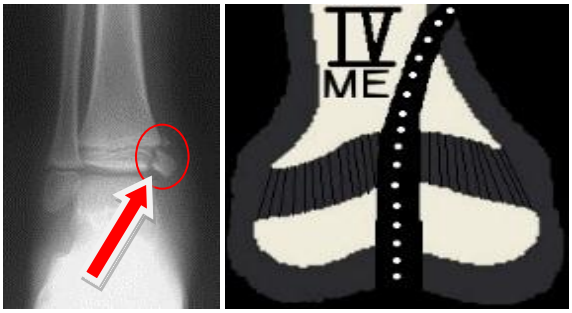

Salter-Harris Fracture: Type V

- This uncommon injury occurs when the end of the bone is crushed and the growth plate is compressed.
- It is most likely to occur at the knee or ankle. Prognosis is poor, since premature stunting of growth is almost inevitable.
  - Crushing injury of the growth plate.
  - Most disastrous since the growth plate is involved, leading to growth stunting.

JAX *In acute setting, Type I and Type V present almost the same. You can only differentiate later on that it is the latter when there is growth stunting/ arrest. (Limb shortening)*

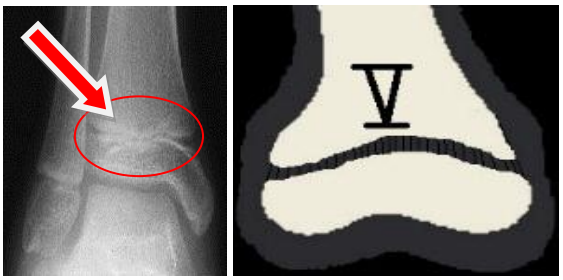

SALTER HARRIS CLASSIFICATION	
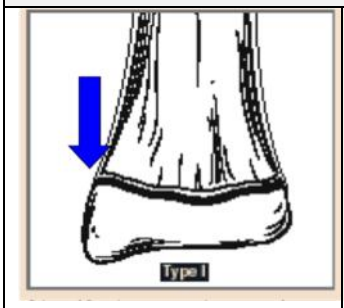 Type I	• Fracture passes transversely through physis separating epiphysis from metaphysis
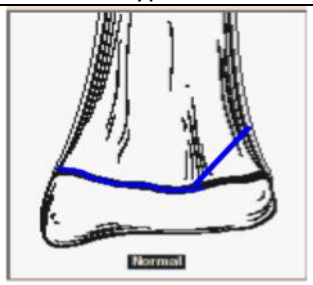 Type II *(blue)*	• Transversely through physis but exits through metaphysis • Triangular fragment (Thurston-Holland fragment)
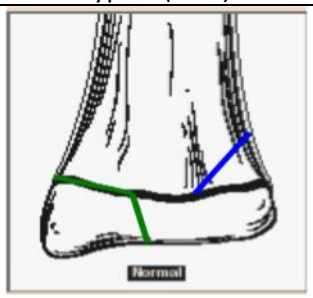 Type III *(green)*	• Crosses physis and exits through epiphysis at joint space

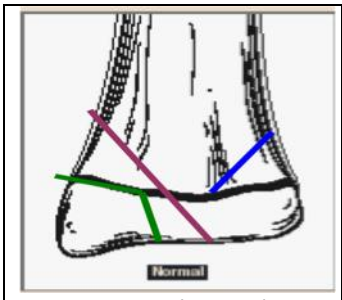 Type IV *(purple)*	• Fracture extends upwards from the joint line, through the physis and out the metaphysis
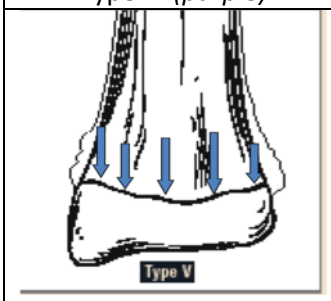 Type V	• Crush injury to growth plate

PEDIATRIC SHOULDER AND UPPER EXTREMITY FRACTURES

- PROXIMAL HUMERUS FRACTURE
- CLAVICULAR FRACTURE
- SUPRACONDYLAR FRACTURE
- LATERAL CONDYLE FRACTURE
- MEDIAL EPICONDYLE FRACTURE
- RADIAL HEAD SUBLUXATION
- FOREARM FRACTURE

PROXIMAL HUMERUS FRACTURE

- Accounts for 5% of fracture in children
- Eighty percent of humeral growth occurs at proximal physis
- Primary vascular supply is the anterolateral ascending branch of anterior humeral circumflex artery

Mechanism of Injury:

- Direct trauma to the posterolateral aspect of shoulder
- Proximal fragment is held by rotator cuff muscles in neutral or in slight abduction and external rotation
- Distal fragment pierces the periosteum anterolateral to biceps tendon and held in adduction by pectoralis major and pulled proximally by deltoid

Clinical Evaluation:

- Presents with pain, dysfunction, swelling, ecchymosis
- Careful neurovascular exam

Treatment:

- Most fractures are manage by closed treatment
- Surgical (indicated if there is displacement; closed reduction or pinnings are used)

Axillary nerve – most common nerve involved in this kind of fracture

CLAVICULAR FRACTURE

- Most common fracture in children
- 90% of obstetric fractures
  - This happens in cases of dystocia when the baby is too large.
- High incidence of concomitant clavicle and OBPP (Obstetric brachial plexus palsy)
- Fracture location:
  - Medial clavicle → physeal fractures→ posteriorly displaced fractures may impinge mediastinum
  - Shaft → **most common**
  - Lateral → may be confused with AC joint dislocation

JAX Check history: Falls from a height and landing on affected shoulder; presenting with pain, tenderness, limitation of movement

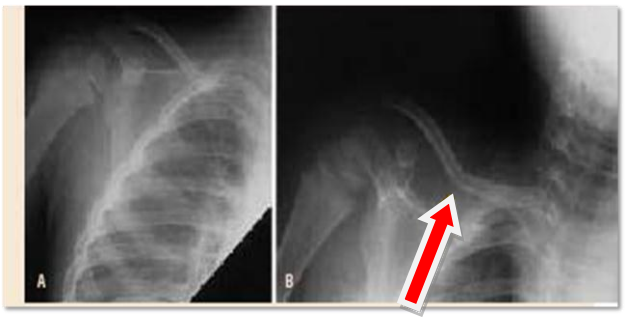

- CLAVICLE - Is the first bone to ossify

Mechanism of Injury:

- Direct trauma of the affected clavicle

- Birth injuries
- Indirect due to fall onto an outstretched hand

Clinical Evaluation:
- Pain on palpation
- Presence of mass
- Crepitus
- Neurovascular exam
- Xray evaluation

Treatment:
- Sling versus figure-of-eight bandage
- Fracture fully healed when patient has painless ROM at shoulder and non-tender to palpation at fracture
- Generally back to full activity by 4 weeks
- Protect from contact sports for 6 weeks
- Warn of the healed 'bulge
  - Assure that it is only a callus formation along the fracture line of the clavicle. It is not a tumor.

SUPRACONDYLAR HUMERUS FRACTURE

- Account for more than half of pediatric elbow fractures
- 95 to 98% are **extension type** (2% flexion type)
- Weakest part of the elbow joint where humerus flattens and flares
  - Olecranon driven into humerus with hyperextension
- Marked pain and swelling of elbow
- Potential for vascular compromise
  - Check pulse
  - Check nerve function in hand
- JAX Neurovascular status checking is important
- JAX Brachial artery – most common injured vessel
- JAX Median nerve, anterior interosseous nerve – most common injured nerve

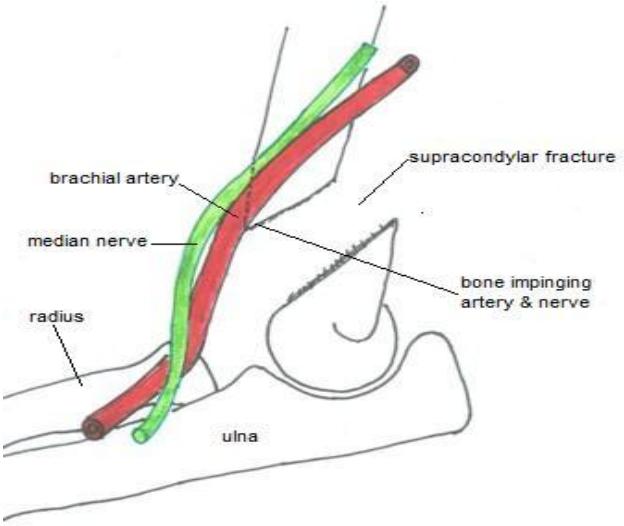

- Sixty percent of all elbow fractures
- Peak incidence: 5-8 years old
- Remodeling in bone decreased AP diameter of bone
- Ligamentous laxity increases likelihood of hyperextension injury
- Anterior capsule is thickened and stronger than posterior capsule
- Periosteal hinge remains intact on the side of displacement

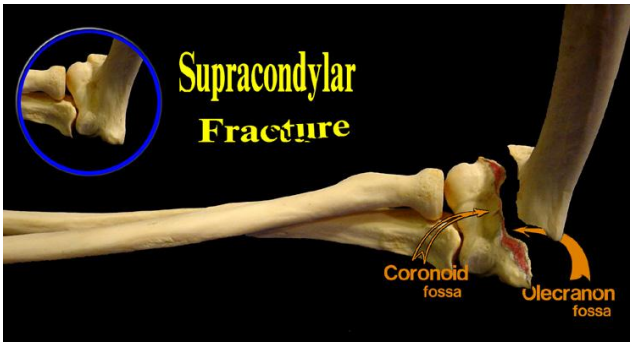

Mechanism of Injury:
- Extension
- Flexion

Clinical Presentation:
- Swollen tender elbow with painful ROM
- Presence of "pucker sign" – anterior dimpling of skin

Lateral X-Ray Positioning

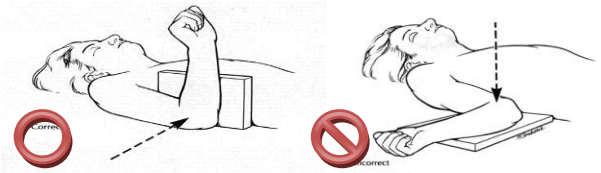

SUPRACONDYLAR FRACTURE CLASSIFICATION

- Type I – non-displaced or minimally displaced

- Type II – displaced distal fragment with intact posterior cortex
- Type III – displaced with no contact between fragment
- Type IV – also a Type III fracture but when open reduction is done, there is instability of reduction; unstable in flexion & extension.

JAX Presence of hematoma formation at anterior portion of the arm, deformity also present.

FAT PAD SIGN (aka Sail Sign)

- Anterior fat pad sign can be normal (caused by effusion of blood due to elbow fracture)
- Posterior always abnormal

JAX Note for radiolucency at the anterior and posterior sides.

Treatment:

- Nonsurgical
  - Type I treated closed with long arm splint in 90 degree elbow flexion
  - Some type II can be managed closed
- Surgical treatment
  - Most type II and type III
  - Cross pinning/ lateral-entry pins with K-wires

Complications:

- **Volkmann ischemic contracture** → most disastrous → due to compression of the brachial artery with casting in >90 degrees of flexion
  - Usually an acute complication

Contracture of the fingers and sometimes the wrist after severe injury in or near the elbow or improper use of a tourniquet interferes with the blood supply to the muscles.

- **Cubitus varus** → gunstock deformity
  - Late complication especially if left untreated or not managed properly.
  - "PINGKAW"

LATERAL CONDYLAR FRACTURES

- 2nd most common elbow fracture and represents 17% of all distal humeral fractures
- Represents 54% of distal humeral physeal fractures
- Less satisfactory outcomes:
  - Diagnosis is less obvious
  - Loss of motion due to intraarticular in nature
  - Higher incidence of growth disturbance
- The ossification center of lateral condyle extends to lateral crista of trochlea
- Lateral condylar physeal fractures are typically accompanied by soft tissue disruption between origins of ECRL (Extensor carpi radialis longus) and brachioradialis

Mechanism of Injury:

- Avulsion injury by common extensor origin due to varus stress
- Fall on extended upper extremity

Clinical Evaluation:

- Presents with little gross distortion of elbow
- Crepitus

Classification:

- TYPE I – fracture line courses lateral to the trochlea and into capitulotrochlear groove (Salter- Harris IV)
- TYPE II – fracture line extends to the apex of trochlea (Salter- Harris II)

Treatment:

- Intraarticular = open reduction
- If non-displaced, can treat with casting
- Posterior splint acutely, elbow 90o
- At follow-up (weekly), check for late displacement
- If stable for 2 weeks, apply long arm cast for another 4-6 weeks

Complications:

- Growth arrest
- Non-union

MEDIAL EPICONDYLE FRACTURE (MEF)

- Comprise 12% of all elbow fractures
- Mechanism of injury is generally avulsion of the medial epicondyle apophysis

An apophysis is a normal developmental outgrowth of a bone which arises from a separate ossification centre, and fuses to the bone later in development.

- Associated with elbow dislocations - 50%
- Post reduction radiograph of elbow dislocation should evaluated for the presence of entrapped medial epicondyle fracture
- In 18-20% of cases of patients with MEF fracture with associated elbow dislocation, there is the presence of entrapped MEF.
- Medial epicondyle is a traction apophysis for medial collateral ligament and wrist flexor
  - Always remember, it is a medial attachment of your medial collateral ligament and your basic flexors (that's why the fracture displaces significantly)
- The fragment is displaced distally, maybe incarcerated in joint 15-18% of the time
- Often associated with fractures of proximal radius, olecranon, and coronoid

Mechanism of Injury:

- Direct trauma to medial epicondyle
- Secondary to elbow dislocation

Clinical Evaluation:

- Presents with pain , tenderness, swelling medially
- Careful neurovascular exam is essential as injury occurs in proximity to ulnar nerve

Treatment:

- Nonsurgical care – mainstay of treatment
  - Closed attempts to extricate an entrapped medial condyle may be undertaken by supinating the forearm, placing a valgus stress on the elbow and extending the wrist and fingers
  - Early motion (within 3 to 5 days) minimizes the risk of elbow stiffness
- Surgical treatment

Two types of Indications:

- **Absolute** – intra-articular entrapment of the medial epicondyle (do ORIF)
- **Relative** – dominant arm in a throwing athlete, weight-bearing extremity in an athlete, ulnar nerve dysfunction
- Technique: ORIF → screw or pin

Insertion of pins

RADIAL HEAD SUBLUXATION

- "Nursemaid's elbow" or "Pulled elbow"
- Comprises 28% of all elbow injuries in children
- Occurs with longitudinal traction on the outstretched arm of a young child as the orbicular ligament subluxates over the radial head

- Usual mechanism of injury is elbow extended and forearm pronated

Clinical Evaluation:

- Presents with appropriate history of sudden longitudinal traction applied to the extended upper extremity often with an **audible snap**
- Initial pain subsides rapidly and patients allows upper extremity to hang in dependent position with refusal to use ipsilateral hand

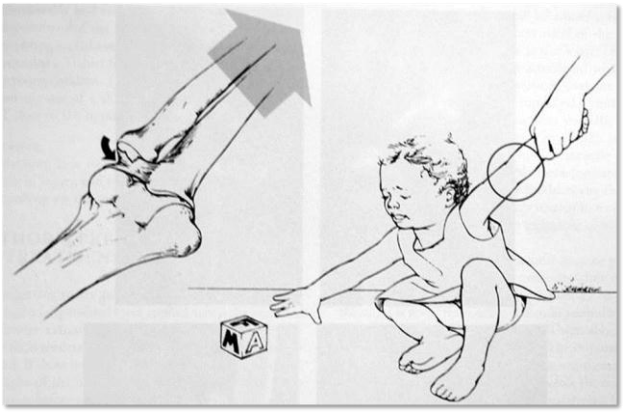

This is a classic picture of a patient with nurse's maid elbow. Management is only close reduction or close treatment.

Treatment:

- Thumb held over the affected radial head, the forearm is supinated and the elbow flexed past 90 degrees
  - Patient is placed is put in a posterior splint for 3 to 5 days then when the swelling subsides, splint can be removed and range of motion exercises of the elbow may be started.

FOREARM FRACTURE

- Very common, comprising 45% of all pediatric fracture (the most common of all pediatric fractures)
- Eighty percent occurs in children >5yrs old
- Peak incidence corresponds to peak velocity of growth when bone is weakest due to dissociation between bone growth and mineralization

Mechanism of Injury:

- Direct trauma to radial shaft or ulnar shaft - most common reason
- Indirect due to fall on outstretched hand

Clinical Evaluation:

- Pain, swelling, crepitus, sometimes variable gross deformity
- Refusal to use affected upper extremity
- Careful neurovascular exam is essential

This is an example of patient with a slightly displaced fracture of the shaft of radius and ulna.

SPECIAL FORMS OF FRACTURE

GALEAZZI FRACTURE

- Middle third and distal third fracture of radius
- Disruption at the DISTAL radio-ulnar joint
- The injury disrupts the forearm axis joint

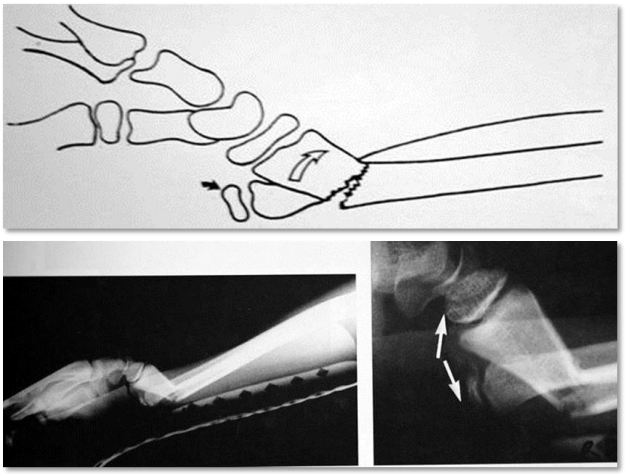

MONTEGGIA FRACTURE

- One type of forearm fracture, fracture at ulnar shaft.
- Disruption at the PROXIMAL radio-ulnar joint The opposite of Galeazzi fracture.

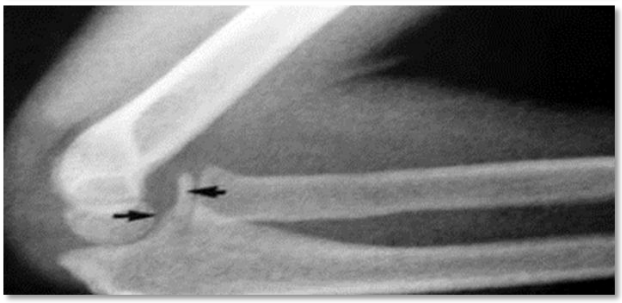

Galeazzi fracture and Monteggia fractures are **fractures of necessity** since surgical management is usually indicated in these types of fractures.

Treatment:

- Nonsurgical (if acceptable, this is usually indicated)
  - Closed reduction and application of cast/ splint
- Surgical treatment
  - Significantly displaced fracture
  - Open fracture

Complications:

- Refracture
- Malunion
- Compartment syndrome

Occurs when the tissue pressure within a closed muscle compartment exceeds the perfusion pressure and results in muscle and nerve ischemia. Presents with decreased sensation, numbness and tingling, paleness of skin, severe pain that gets worse, and weakness.

- Loss of pronation and supination

Notes by: Sameon N, Otico F, Tajada D, Catague R
References: audio, JAX notes, powerpoint, **Fractures in Children by Rockwood and Wilkin 6th Ed.**